Check for updates

JOURNAL OF LAPAROENDOSCOPIC & ADVANCED SURGICAL TECHNIQUES
Volume 33, Number 10, 2023
© Mary Ann Liebert, Inc.
DOI: 10.1089/lap.2023.0070

Full Reports

Open camera or QR reader and scan code to access this article and other resources online.

Intercostal Nerve Cryoablation for Postoperative Pain Control in Pediatric Thoracic Surgery: A Scoping Review

Krista Lai, MD,[1] R. Scott Eldredge, MD,[1] Michael Zobel, MD,[2] Angela Hargis-Villanueva, MD,[1] Andrew Ostlie,[3] and Benjamin E. Padilla, MD[1,3]

Abstract

Background: Cryoanalgesia uses the application of cold temperatures to temporarily disrupt peripheral sensory nerve function for pain control. This review outlines the principles of cryoablation, clinical applications, and clinical data for its use in pediatric thoracic surgery.
Methods: A comprehensive PubMed search was performed using the principal terms and combinations of cryoablation, cryoanalgesia, Nuss, Nuss repair, pectus, pectus excavatum, thoracic surgery, thoracotomy, and chest wall. Pediatric articles were reviewed and included if relevant. Adult articles were reviewed for supporting information as needed. Reference lists of included articles were reviewed for possible additional sources.
Discussion: The scientific and clinical principles of cryoablation are outlined, followed by a focused review of current clinical application and outcome data.
Conclusion: Postoperative pain is a major challenge following thoracic surgery. Cryoanalgesia is emerging as an adjunct in pediatric thoracic surgery, particularly for the Nuss procedure or minimally invasive repair of pectus excavatum. It effectively controls pain, decreasing postoperative opioid use and hospital length of stay with few short-term complications. Although more long-term studies are needed, early evidence suggests there is reliable return of sensation to the chest wall and long-term neuropathic pain is rare.

Keywords: cryoablation, cryoanalgesia, thoracic surgery, Nuss procedure, pediatric, pectus excavatum

Introduction

The modern form of cryosurgery was described in 1962 by the neurosurgeon, Irving S. Cooper, who designed a cryosurgical probe that used liquid nitrogen to ablate the ventrolateral thalamus to alleviate tremors in Parkinson's patients.[1] Shortly thereafter, Lloyd et al. reported the successful treatment of 52 patients with intractable pain following cryoablation of peripheral nerves, including intercostal nerves, sacral nerve roots, and facial nerves.[2] Cryoanalgesia is increasingly used in thoracic surgery for postoperative pain control. Its mechanism of action relies on the temporary disruption of nerve function to provide analgesia, with subsequent nerve regeneration and return of sensation.

This review outlines the principles of cryoablation, its clinical applications, and the available outcome data for its current use in adult and pediatric thoracic surgery.

Methods

A comprehensive PubMed search of discussion topics was performed using the principal terms and combinations of cryoablation, cryoanalgesia, Nuss, Nuss repair, pectus, pectus excavatum, thoracic surgery, thoracotomy, and chest wall. Pediatric articles were reviewed and included if relevant. Articles were excluded if they did not discuss cryoanalgesia or thoracic surgery. Adult articles were reviewed for

[1]Division of Pediatric Surgery, Phoenix Children's Hospital, Phoenix, Arizona, USA.
[2]Division of Pediatric Surgery, University of California San Francisco, San Francisco, USA.
[3]Department of Child Health, University of Arizona School of Medicine, Tucson, Arizona, USA.

supporting information as needed. Reference lists of included articles were reviewed for possible additional sources.

This review focuses on the history, principles, and current clinical applications of cryoablation for postoperative pain control in thoracic surgery.

Discussion

Scientific principles of cryoablation

History and biology. Cryoanalgesia capitalizes on the remarkable potential of peripheral nerve regeneration following injury. Within a nerve, each axon is surrounded by a layer of connective tissue called the endoneurium. Groups of axons are bundled together into fascicles and wrapped in perineurium. The entire nerve is wrapped in an outermost layer of connective tissue called the epineurium (Fig. 1). Following damage to the axon of a peripheral neuron, the axon can regenerate if the cell body of the neuron is intact. Axonal injury, be it mechanical or thermal, results in Wallerian degeneration distal to the site of injury. The injured axon loses cell membrane integrity, and the axonal cytoskeleton breaks down. The myelin sheath next undergoes degeneration followed by infiltration of macrophages and Schwann cells, which clear the cellular debris, leaving behind the connective tissue sheaths: the endoneurium, perineurium, and epineurium.[3,4]

Schwann cells proliferate, aligning along the connective tissue tubes (Büngner bands), and produce neurotrophic factors that promote and guide axonal regeneration. Within days of injury, a growth cone forms at the distal tip of the axon, proximal to the injury site. The growth cone migrates toward the Büngner bands, paving the way for axonal regeneration.[3] Peripheral nerves regenerate at a rate of 1–2 mm/day in more distal segments and up to 2–3 mm/day in proximal segments, eventually reinnervating the target tissue.

The goal of cryoanalgesia is controlled thermal injury to the targeted nerve, resulting in disruption of the axons, while preserving the neural sheaths and allowing subsequent axonal regeneration (Fig. 1). Cryoablation induces thermal nerve injury at the site of probe contact through formation of intracellular and extracellular ice crystals, leading to changes in cellular osmolality and permeability and subsequent axonal injury.[5] The neural sheaths comprise fibrous connective tissue that are more resistant to damage from freezing.[6] Seddon classified the degree of nerve injury according to the extent of demyelination and prognosis for neuroregeneration.[7]

Alternatively, Sunderland classified nerve injury by the extent of damage to individual elements of the nerve (Table 1).[8] Zhou et al. studied the effects of freezing sciatic nerves of rabbits to temperatures between –20°C and –180°C.[6] The morphology of the frozen nerves were studied using light and electron microscopy, while the nerve function was assessed using somatosensory evoked potentials, sensory conduction velocity, and electromyogram at various intervals after freezing. There was no morphologic or functional change in nerves at –20°C. Cryoinjury to temperatures between –60°C and –100°C resulted in ''axonotmesis'' per Seddon taxonomy, with axonal degeneration and neural sheath preservation, and subsequent functional recovery. At these temperatures, the endoneurium, perineurium, and epineurium remained intact, resulting in a Sunderland Grade II injury.

At –140°C and colder, there was destruction of basal membranes of the nerve sheath and permanent nerve damage.[6] Similarly, Hsu and Stevenson found that cold application at –60°C to the rat tibial nerve resulted in the loss of hind limb motor function, with axonal demyelination and degeneration, but preservation of the epineurium and perineurium seen on pathologic review at 2 weeks.[9] There was complete axonal regeneration, remyelination, and functional recovery by 16 weeks. Peripheral nerve cryoablation to temperatures between –60°C and –100°C ''transects'' the axons from within, while preserving the nerve sheath to allow for axonal regeneration (Fig. 1).

To investigate factors influencing duration and efficacy of cryoablation, Evans et al. studied different freezing cycles

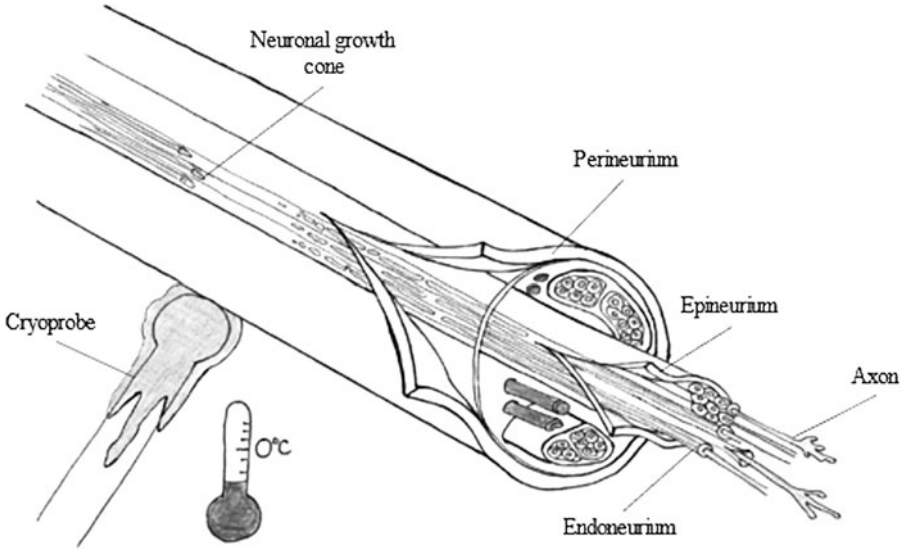

FIG. 1. Axonotmesis induced by cryoablation. Axon thermal injury at the point of cold probe contact results in downstream Wallerian degeneration of the axon. The endoneurium, perineurium, and epineurium remain intact. Within days of axonal injury, the growth cone forms and axonal regeneration begins.

Table 1. Summary of Nerve Injury

Seddon	*Sunderland*	*Tissue affected*	*Loss of function*	*Recovery*	*Associated temperature*
Neuropraxia	Grade I	Myelin	Temporary motor and sensory	Minutes to weeks	+10°C to −20°C
Axonotmesis	Grade II Grade III Grade IV	Axon, Myelin Axon, endoneurium Axon, endoneurium, perineurium	Temporary motor and sensory	Weeks to months.	−20°C to −100°C
Neurotmesis	Grade V	Axon, endoneurium, perineurium, epineurium (transection)	Complete loss of function	Recovery inadequate. Need surgery	Colder than −140°C

Adapted from Menorca 2013, Ilfeld 2020.

applied to rat sciatic nerves.[10] They manipulated the freezing temperature and the duration of freezing and monitored for sensory and motor recovery. At temperatures warmer than −20°C, the number of days to return of sensation was significantly fewer than colder temperatures. However, when cooled to less than −20°C, temperature did not influence recovery time. Duration of cryoablation similarly had no significant impact on the return of sensation when temperatures were −20°C or colder.

The authors specifically note the unpredictability of sensory and motor effects observed when temperatures applied ranged from 0°C to −20°C. More recently, Moorjani et al. performed cryoablation of intercostal nerves in dogs at a temperature of −50°C for 30, 60, 90, and 120 seconds, and subsequently biopsied the nerves at regular intervals over 6 months.[11] Axonal degeneration with intact endoneurium (axonotmesis injury) was observed for all cryoablation durations tested. Histologically, axonal regeneration was complete after 1 month in the 30- and 60-second groups. Increased time to the start of regeneration and subsequent neuronal recovery were observed among the 90- and 120-second groups; however, the timing of this process was not reported by the authors. Their findings suggest that duration of cold application affects the rate of axonal regeneration, but no mechanism is offered to explain this finding.

Beazley et al. documented the timeline of peripheral nerve regeneration following facial nerve cryoablation in primates.[12] A cryoprobe was applied to the right facial nerve at −40°C for a total of 4 minutes. Following this application, complete nerve palsy was observed; recovery of normal nerve function began at 5 weeks with complete recovery observed at 9 weeks post-cryoablation. Axonal regeneration occurred at a rate of 1–3 mm per day. The histological studies performed in the literature were conducted on animals with different never fiber diameters; it is unclear how these findings translate to humans. These studies demonstrate that there is a temperature threshold for achieving axonal injury with nerve sheath preservation. However, the effects of the duration of cryoablation, repeated exposure, and nerve size are less clear.

Mechanism of cooling. Commercially available cryoprobes consist of an inner single-walled aluminum tube, covered with an insulating outer tube. The inner layer is thermally conductive and serves as the conduit down which pressurized gas (usually nitrous oxide or carbon dioxide) travels (Fig. 2). Rapid cooling of the cryoprobe tip results from the Joule-Thomson effect; as gas is released into the larger diameter, low-pressure outer tube, it rapidly expands and absorbs surrounding heat, thereby cooling the tip of the probe.[13]

The effect of cryoablation on tissues surrounding the desired point of contact is mitigated by the heat sink phenomenon, where adjacent blood flow within adjacent

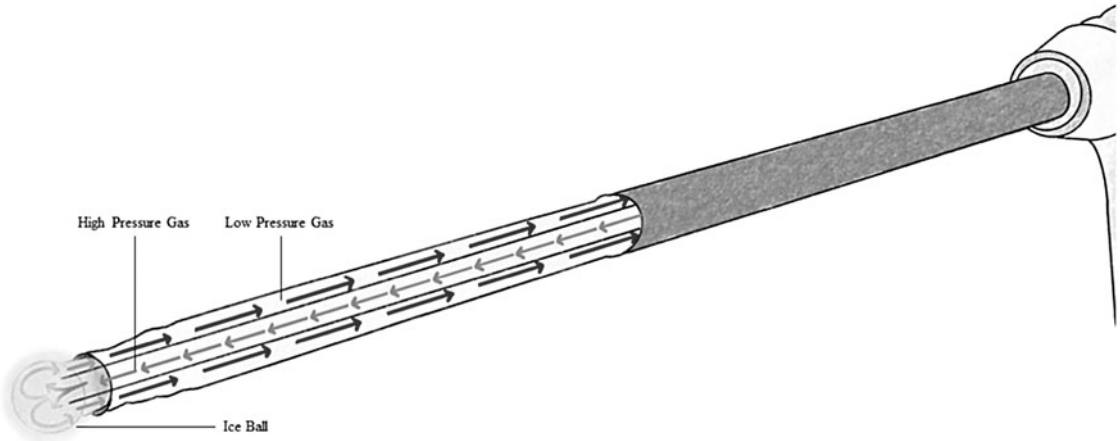

FIG. 2. Pressurized gas travels down the inner tube. Rapid cooling of the probe tip occurs as the gas is released into the larger diameter outer tube at relatively lower pressures, absorbing surrounding heat (Joule-Thomson effect).

vessels quickly disperses and equilibrates local temperature change.[14] After cooling is complete, the cryoprobe undergoes an active defrosting phase to permit detachment of the probe from the tissue without causing mechanical injury.[15] This defrost phase is controlled to prevent reheating of the frozen tissue, as slow thawing of frozen tissue is associated with maximal axonal injury effect.[16]

Clinical principles of cryoanalgesia

Cryoablation affects both motor and sensory nerves. Thoracic surgery is painful and well suited for intercostal nerve cryoablation, as the motor component is almost exclusive to the intercostal muscles, which are not vital to quiet respiration.[17,18] In addition, the intercostal nerves are easily accessible and identified below the ribs. In contrast, nerves to the abdomen and extremities are usually deep in the tissue and loss of motor innervation would result in disability.

The myotomes and dermatomes of the thoracoabdominal cavity are key considerations. The nerve roots at T1 and T2 are associated with the cervical sympathetic chain and provide sensory and motor innervation to the upper extremity.[19] Cryoablation of the T1 and T2 can result in Horner's syndrome or functional deficits to the upper extremity and should be avoided. The intercostal nerves from T3 to T8 contain sensory and motor nerves. The motor nerves of T3–T8 provide innervation of intercostal muscles. Loss of intercostal muscle function is well tolerated.[17,18] Cryoablation of intercostal nerves T3–T8 results in the loss of sensation from the manubrium to just below the xiphoid and provides analgesia for most thoracic operations.

Cryoablation of intercostal nerves T9 and lower should be undertaken with caution, as these nerves provide motor innervation to the abdominal musculature and can theoretically result in laxity of the abdominal wall. Nerve function is disrupted distal to the site of cold application; therefore, the more proximal the cryoprobe is applied on the nerve, the greater the resulting area of analgesia. There is theoretical concern that applying the cryoprobe near the nerve root as it emerges from the neural foramen could result in injury to the spinal cord. Manufacturer recommendations suggest placing the cryoprobe a minimum of 4 cm from the base of the spine, or 2 cm from the ganglia.[20] In general, it is recommended to perform cryoablation at the intercostal level of the thoracotomy incision as well as at two intercostal levels above, and two levels below the incision.

The cryoprobe can be applied to the intercostal neurovascular bundle through an intrathoracic or extrathoracic approach. An intrathoracic approach is generally employed for an open thoracotomy or video-assisted thoracoscopy. Cryoanalgesia is increasingly used during thoracoscopic operations and the cryoprobe is similarly applied under direct thoracoscopic visualization. Alternatively, the cryoprobe can be applied extrathoracically; the cryoprobe is tunneled subcutaneously and applied to the intercostal neurovascular bundle. To date, there is no head-to-head comparison of external versus internal application of cryoanalgesia.

Thoracic cryoanalgesia in adults

Briefly, the literature in adults describes more varied applications of cryoanalgesia. Recently, Park et al. published a systematic review and meta-analysis of cryoablation for postoperative analgesia in adults, which included 20 articles pertaining to thoracotomies.[21] In general, cryoablation was associated with decreased opioid use compared to intercostal nerve blocks, but not compared to epidurals. There was variation in the technique, ranging from −20°C to −70°C for 30–120 seconds over 3–8 intercostal nerves. However, most articles were published over 10 years ago and cryoanalgesia devices and technology have evolved in the interim. Cha et al. reached a similar conclusion in their systematic review on the efficacy of intercostal nerve cryoablation as an analgesic adjunct to other modalities.[22] They provided a recommendation that cryoablation leads to decreased postoperative narcotic use and pain scores (grade 2A and 2C evidence respectively) in patients undergoing a thoracotomy.

Lau et al. randomized patients undergoing minimally invasive thoracotomy heart valve surgery to cryoablation plus standard-of-care opioids or standard-of-care opioids alone.[23] The primary endpoint was forced expiratory volume in 1 second (FEV1), which was noted to be significantly higher in the cryoablation group up to 48 hours postoperatively only. While there was a 13% decrease in overall opioid use during hospital stay for the cryoablation group, it was not statistically significant. In another study, Tung et al. used cryoablation as an adjunct to their institutional standard multimodal regimen in 10 patients undergoing robotic-assisted pulmonary resection.[24] Both inpatient and outpatient opioid use were significantly lower in the cryoablation group. Seven patients who received cryoablation were discharged home without an opioid prescription.

Several studies examine cryoablation for rib fractures, which are associated with significant morbidity and mortality. Finneran et al. used ultrasound-guided percutaneous cryoablation in a series of 5 patients with traumatic rib fractures, demonstrating decreased pain scores and opioid use and increased incentive spirometry volumes.[25] At 3-month follow-up, no patient reported neuropathic pain. When combining cryoablation with surgical stabilization of rib fractures, there is conflicting evidence on its effect on postoperative opioid use.[26,27] When looking at pain scores as a clinical endpoint, Zhao et al. found significant improvement in postoperative pain scores in 13 patients.[28] However, this study lacked objective measures such as opioid use and fails to distinguish whether the improvement in pain score was the result of cryoanalgesia or the concomitant rib stabilization procedure.

Thoracic cryoanalgesia in children

Minimally invasive repair of pectus excavatum. Minimally invasive repair of pectus excavatum (MIRPE), or the Nuss procedure, is the most commonly reported application of cryoanalgesia in the pediatric population. MIRPE is typically associated with significant postoperative pain, as the chest is instantaneously remodeled with insertion of bars behind the sternum.[29] Numerous regimens of multimodal analgesia are described, including combinations of thoracic epidural, intravenous patient-controlled analgesia (PCA), indwelling catheter infusions, local or regional nerve blocks, and oral analgesia (opioids, anti-inflammatories, and gabapentinoids).[30–35] A standardized approach to perioperative pain management has not been established.

Cryoanalgesia as a pain-control strategy following MIRPE was first reported by Keller et al. in 2016.[36] This retrospective

study compared 26 patients with cryoanalgesia to 26 patients with a thoracic epidural. The cryoprobe was tunneled subcutaneously and applied to the intercostal neurovascular bundle from outside the chest wall with thoracoscopic visualization of the intrathoracic formation of a ''frost ball.'' Cryoanalgesia patients used less postoperative opioids and had a shorter hospital length of stay (LOS). In 2019, Graves et al. reported a randomized controlled trial comparing cryoanalgesia to thoracic epidural in patients undergoing MIRPE.[37]

Each treatment arm included 10 patients, all of whom received a PCA postoperatively. Cryoanalgesia was performed bilaterally to the intercostal nerves, T3–T7, for a 2-minute duration at each nerve, at a temperature of –60°C. Pain scores were similar between the study cohorts; however, the cryoanalgesia group required 61% less opioid overall than the epidural group.

Furthermore, the median LOS for the cryoanalgesia group was 3 days compared to 5 days for the epidural group. These findings were substantiated by Parrado et al. who compared cryoanalgesia to thoracic elastomeric pain pumps and found similar pain scores between groups, with decreased opioid requirements in the cryoanalgesia group.[38] Table 2 provides a summary of the pediatric experience using cryoanalgesia in the repair of pectus excavatum. Most were small, single-institution retrospective studies, with the largest pediatric cohort of 350 patients.

Overall, most groups found that cryoanalgesia provided equally effective pain control compared to other strategies such as PCA, thoracic epidural, and elastomeric pain pumps. Importantly, cryoanalgesia was associated with decreased inpatient opioid use and shortened LOS. Of the studies that tracked postoperative neuropathic pain, no patient had lasting effects. There was more uniformity in the cryoablation technique in the pediatric experience compared to techniques reported in the adult literature. In children, cryoanalgesia was generally applied to 4–5 intercostal nerves to a temperature of –60°C for 2 minutes.

The use of cryoablation has repeatedly been associated with decreased LOS; many studies have demonstrated the ability for safe discharge on postoperative day 1.[39–43] In 2022, Rettig et al.[41] conducted a retrospective study of 30 patients undergoing the MIRPE with cryoablation to determine the safety of same-day discharge. On postoperative day 0, 10 patients were discharged home after meeting appropriate criteria (tolerate oral intake, pain adequately controlled with oral pain medications, able to void spontaneously, and no major pneumothorax). Of the 10 patients, 1 returned to an urgent care for constipation.

An additional potential benefit of using cryoablation in the MIRPE is decreased overall hospital costs; however, there are conflicting reports in literature, which may be due to differences in charges between hospital systems. Graves et al. commented that the increased operating room costs including equipment and operative time were offset by a decreased LOS.[37] Three separate groups have quantified a cost benefit, noting ~$2,000–$7,000 less in cryoablation patients; $14,072 versus $21,021,[42] $21,924 versus $23,694,[43] $15,976 versus $18,336.[44] However, Mehl et al. reported cryoablation being associated with increased total hospital costs in comparison to PCA ($11,145 versus $8975, $P < .01$), but there was no significant cost difference when compared to epidural or PCA with peripheral nerve block.[45] Operating room supplies was the primary factor for increased cost with cryoablation.

Other chest wall procedures. Cryoanalgesia is also reported in open thoracic surgery in children. A prospective study of 9 patients by Pilkington et al.[46] demonstrated that intercostal nerve cryoablation reduced LOS by 2 days following the modified Ravitch for pectus deformities compared to thoracic epidural analgesia (Table 2). There was an initial benefit with improved pain control scores in the cryoanalgesia group on POD#2, but no significant difference overall in total postoperative opioid use or discharge prescription. The LOS was shortened by 2 days with cryoablation.

Similarly, Gologorsky et al. retrospectively reviewed the postoperative pain scores of 5 patients who underwent open repair of pectus carinatum with cryoablation.[47] The median LOS was 1 day and only one patient reported a pain score higher than 0. One week postoperatively, all patients reported scores of 0 and none developed neuropathic pain by 1 year.

Chen et al.[48] performed a retrospective study of 32 patients who underwent 53 thoracotomies for oncological resection. The use of cryoablation was employed in 14 of the 53 thoracotomies; patients with cryoanalgesia used significantly less opiates during hospitalization and at discharge. They also found significantly lower pain score among those with cryoanalgesia by postoperative day 4.

The use of cryoanalgesia has also been reported in the treatment of slipping rib. Krista Lai et al.[49] conducted a retrospective review of 98 patients who underwent treatment for slipping rib with cartilaginous rib excision. Of these patients, intercostal nerve cryoanalgesia was employed in 30. The researchers similarly found a decrease in opiate use and length of hospitalization with the use of cryoanalgesia.

Complications

There is a range of potential complications arising from the use of cryoablation. While short-term complications are described in the articles previously referenced, there is a paucity of literature dedicated to long-term effects. In Park et al.'s systematic review of thoracic cryoanalgesia in adults, pooling of two studies in the meta-analysis showed cryoablation significantly improved persistent pain at 1 month postoperatively.[21] However, they noted incomplete and inconsistent reporting of adverse events, which precluded any further pooling and analysis of other complications. The increase of cryoablation during MIRPE in the pediatric population discussed in the literature has led to a more robust understanding of complications associated with cryoablation.

Sensation. Long-term sensory loss is a concern following cryoablation, but as of yet, prospective data regarding the duration of symptoms are limited. A number of retrospective studies have investigated numbness and hypoesthesia following intercostal nerve cryoablation with an incidence of persistent hypoesthesia ranging from 15% to 38% at 6 months.[11,40,50–53] A retrospective study performed in 2022 of 40 patients treated with cryoanalgesia during MIRPE found that at 6 months postoperatively, 15% of patients had residual chest wall hypoesthesia. On physical examination, a 2 cm band of residual numbness below the nipple was observed in 66% of patients with persistent

Table 2. Summary of Cryoablation Used During the Repair of Pectus Excavatum and Pectus Carinatum

Study				Cryoablation technique				Postoperative outcomes discussed		
Author/Year	Type of study	Operation	No. of cryo patients	Temperature (°C)	Time	Level	Control	Opioid Use	LOS	Neuropathy
Keller (2016)[36]	Retrospective review	MIRPE	26	−60	2 minutes	T4–T7	TE	↓	↓	—
Graves (2017)[50]	Retrospective review	MIRPE	10	−60	2 minutes	2 above and below bar	TE	N	↓	1 patient with anterior chest stinging 1 month postoperatively treated with gabapentin
Harbaugh (2018)[59]	Retrospective review	MIRPE	19	−60	2 minutes	4–5 levels	TE	↔	↓	—
Morikawa (2018)[60]	Retrospective review	MIRPE	6	n/a	n/a	n/a	MM	↓	↓	—
Graves (2019)[37]	Randomized Control	MIRPE	20	−60	2 minutes	T3–T7	TE	↓	↓	similar neuropathic pain scores up to 1 year postoperatively
Parrado (2019)[38]	Retrospective review	MIRPE	45	−60	2 minutes	T4–T7	EPP, MM	↓	↔	—
Sujka (2018)[72]	Retrospective review	MIRPE	9	n/a	2 minutes	T4–T7	TE ± PCA	↓[a]	↓	—
Pilkington (2020)[46]	Retrospective review	Modified Ravitch	9	−60 to −65	2 minutes	T4–T8 at surgeon discretion	TE	↔	↓	—
Aiken (2021)[71]	Retrospective review	MIRPE	35	−60	2 minutes	T3–T7	TE, PCA	↓	↓	2 patients with neuralgia treated with gabapentin up to 6 weeks postoperatively
Arshad (2021)[62]	Retrospective review—case matched	MIRPE	35	n/a	n/a	n/a	n/a	N	↓	—
Arshad (2021)[62]	Retrospective review	MIRPE	20	n/a	n/a	T3–T7	TE, PCA	↓	↓	—
Gologorsky (2021)[47]	Retrospective review	Open repair pectus carinatum	5	−60	2 minutes	variable	n/a	N	Y	None developed neuralgia
Rettig (2021)[44]	Retrospective review	MIRPE	40	−60	2 minutes	T3–T7	TE	↓	↓	2 patients had transient neuropathic pain treated with gabapentin
Sun (2021)[58]	Retrospective review	MIRPE	65	−65 to −70	2 minutes	T3–T7	TE, PCA, EPP, ICB	↓	↓	Significantly higher (6%) rate of allodynia compared to non-IC (1%) for minutes. 3 months postoperatively

(*continued*)

Table 2. (Continued)

Study				Cryoablation technique				Postoperative outcomes discussed		
Author/Year	Type of study	Operation	No. of cryo patients	Temperature (°C)	Time	Level	Control	Opioid Use	LOS	Neuropathy
Torre (2021)[73]	Prospective pilot study	MIRPE	7	−70	2 minutes	T3–T8	n/a	Y	Y	–
Lai (2022)[69]	Retrospective review	MIRPE	50	−40	2 minutes	T3–T7	EPP MM	↓	↓	—
Lai (2022)[39]	Retrospective review	MIRPE	350	−40	2 mins	T3–T7	n/a	—	—	6% of patients with neuropathic pain at 2–3 months postoperatively
Zeineddin (2023)[42]	Retrospective review	MIRPE	100	−60	1 minutes	T3–T7	ICB+PCA	↓	↓	Similar neuropathic pain scores at 3 months postoperatively
Mehl (2022)[45]	Retrospective review	MIRPE	98	−60 to −80	2 minutes	T3–T7	PCA, TE, PCA+INB	↓	↓	—
Rettig (2022)[41]	Retrospective review	MIRPE	15	n/a	n/a	T3–T7	ICB	↓	↓	No long-term neuropathy in either group at 7.5 months postoperatively
DiFiore (2022)[40]	Retrospective review	MIRPE	40	−67	2 minutes	T3–T8	PCA w/cryo	↓	n/a	No neuropathic pain at 12 months postoperatively
Clark (2022)[43]	Retrospective review	MIRPE	75	−65	2 minutes	T3–T6	MM	↓	↓	—
Lai (2023)[49]	Retrospective review	MIRPE+ slipping rib syndrome	30	−60	2 minutes	T4–T7	MM	↔	↓	—

[a]The cryoablation group had shorter time to discontinuation of oral opioid analgesia.

EPP, elastomeric pain pump; ICB, intercostal nerve block; LOS, length of stay; MIRPE, minimally invasive repair of pectus excavatum; MM, multimodal medication; n/a, not available; PCA, patient-controlled analgesia; TE, thoracic epidural.

hypoesthesia at 6 months. By 1 year postoperatively, all patients had return of chest wall sensation.[40] A 2019 randomized trial also found complete chest wall sensation return in patients 14–31 years of age, who underwent the MIRPE with cryoablation at 1 year postoperatively.[37]

More recently, Zobel et al. observed a difference in return of normal chest wall sensation following intercostal cryoablation during the MIRPE based on patient age.[54] Adult patients experienced prolonged numbness relative to pediatric patients (10.7 versus 3.4 months, $P = .003$). Among all patients, the frequency of numbness lasting longer than 12 months following cryoablation was 9.3%, and only 3.3% among children. These data support the premise that nerve healing and regeneration are accelerated in younger patients, which has been corroborated by numerous studies examining the effect of age on the recovery rate following peripheral nerve reconstruction/injury.[55–57]

Neuropathic pain. Neuropathic pain is a reported complication following cryoablation. The pathophysiology of neuropathic pain is likely due to failure of peripheral nerve fibers to fully regenerate within the remaining axonal sheath following Wallerian degeneration. The incidence may vary based on patient age. Zobel et al. employed the S-LANSS, a validated questionnaire designed to quantify neuropathic symptoms, in adult and pediatric patients who underwent cryoablation during MIRPE. The incidence of neuropathic pain was significantly lower for patients younger than 21 years.[54]

Specifically, no patient younger than 21 years experienced neuropathic pain, defined as an S-LANSS score greater than 12. Among the 5 (38.5%) adult patients with neuropathic pain at 1 month, 40% resolved with the initiation of gabapentin alone; in total, 23% of the patients older than 21 years experienced neuropathic pain more than 6 months postcryoablation. In another study of pediatric patients with cryoablation during MIRPE, Sun et al. reported that 6% of patients experienced allodynia, between 3 months and 1 year after surgery; they observed complete resolution of symptoms in all patients by 1 year postcryoablation, using medical management or biofeedback.[58]

The incidence of neuropathic pain following cryoablation varies within adult literature. Lau et al. reported that 1.6% (1/63) of patients who underwent minimally invasive cardiac surgery with cryoanalgesia had allodynia at 6 months, symptoms were self-limited, and improved without intervention by 10 months postoperatively.[23] Tung et al. similarly observed 10% (1/10) of patients who underwent cryoablation for minimally invasive thoracic surgery, who experienced neuralgia postoperatively, which resolved after 1 month of gabapentin therapy.[24] In contrast, higher rates of neuropathic pain have been reported in open thoracic surgery.

Mustola et al. studied adult patients who underwent thoracotomy with the utilization of cryoanalgesia. They reported rates of neuropathic pain in 55% of patients at 8 weeks; symptoms persisted in 30% of patients at 6 months[52] Yang et al. reported a similar incidence of neuropathic pain of 40% at 6 months in patients who underwent thoracotomy with cryoanalgesia.[51] In summary, neuropathic pain is a potential consequence of cryoablation, although the risk of development of neuropathic pain in pediatric patients is reported to be lower than adults. Symptoms in most patients can be managed medically with a high rate of resolution of symptoms.

Delayed pneumothorax. Delayed pneumothorax is uncommon, but can be a significant complication following intrathoracic cryoablation with reported rates of 0%–11% of cases.[38,39,58,59] In most cases, delayed pneumothorax is thought to be attributed to unintentional contact of the lung tissue with the cryoprobe. The site of injury does not immediately lead to bronchial-alveolar communication to the thoracic cavity. Over time, the site of cryoinjury results in tissue necrosis and a delayed air leak. Parrado et al. reported a 9% incidence of delayed pneumothorax requiring postoperative thoracostomy tube placement.[38] The investigators suggest that aside from direct contact with the cryoprobe, lung injury occurs as a result of contact between the lung and frozen chest wall. The authors propose allowing the chest wall to thaw for 3 minutes before lung expansion.

An additional strategy to reduce parenchymal contact with the probe is single-lung ventilation using a double-lumen endotracheal tube; however, Graves et al. still observed the development of a delayed pneumothorax in 1 patient (1/10) with this strategy.[37] Morikawa et al. described a novel strategy for avoiding direct contact with pulmonary tissue and the cryoprobe by placing a cut 20-French chest tube over the cryoprobe to reduce potential contact surface area; with this strategy, they report no postoperative pneumothorax in their cohort of 6 patients.[60] Surgeons should be mindful of the cryoprobe location when performing intrathoracic cryoablation, given the risk of delayed pneumothorax due to direct pulmonary parenchymal contact with the cold cryoprobe.

Wound complications. A theoretical risk of cryoablation is increased wound complications due to the association of perioperative patient hypothermia and wound complications.[60,61] The development of patient hypothermia during cryoablation is likely mitigated by the ''thermal sink'' effect of the intercostal vessels. In 4 studies, 3 of which were conducted in pediatric patients undergoing MIRPE[58,59,62,63] found no significant difference in the incidence of surgical site infection between the patients with received cryoablation and those who did not. Bundrant et al. reviewed perioperative core body temperatures of 35 patients who underwent MIPRE with and without cryoablation.[64] The authors found that patients with cryoablation had a significantly lower median body temperature in the recovery room than those without cryoablation; however, they found no difference in surgical site infection between patient with and without cryoablation.

While a thermal injury similar to frostbite has been reported with the use of cryoablation to treat an aneurysmal bone cyst,[65] there is no specific mention of this complication in the chest wall literature. Careful application of the cryoablation probe to tissue is key to preventing wound complications. While the shaft of the probe does have a protective covering layer, it is not completely insulating, and caution should be taken to prevent contact of the probe tip and shaft with lung intrathoracically and skin extrathoracically.

Bar slippage. Following MIRPE, bar displacement resulting in inadequate chest wall correction and reoperation occurs in 2%–3% of patients.[66–68] Bar stabilization techniques and activity restrictions may help mitigate the risk of bar displacement. Two studies found significantly increased

rates (8%–12%)[36,58] in cryoablation groups compared to controls, while another reported a rate of 0.6% in a series of 350 cryoablation patients.[39] The slippage is potentially explained by decreased pain and increased movement postoperatively. Care should be taken to ensure bar stabilization and compliance with activity restrictions.

Pulmonary function. Intercostal muscles play a complementary role in quiet respiration,[17] making intercostal nerve cryoablation an attractive method of analgesia with potentially minimal effect on pulmonary function. Lai et al. examined incentive spirometry volumes as a measure of pulmonary function following MIRPE procedure and found no difference between the cryoablation, elastomeric pain pump, and multimodal regimen alone groups.[69] Within adult thoracotomy literature, Rooney et al. compared the pulmonary function tests of patients who received either transcutaneous nerve stimulation (TNS) or cryoablation as an analgesic adjunct.[70]

The cryoablation group had lower forced vital capacity (FVC), FEV1, and negative inspiratory force (NIF) pressures on POD#1 compared to the TNS and control groups. However, by POD#5, the cryoablation group had recovered with significantly better FVC and FEV1 volumes than both groups and improved NIF than the control group. In more recent studies, the cryoablation group achieved better FVC and FEV1 volumes throughout the postoperative period, but the differences were not significant.[11] Yang et al. also reported improved FVC and FEV1 volumes postoperatively with cryoablation added to a thoracic epidural.[51] However, only the POD#7 FVC reached significance.

Conclusion

Cryoanalgesia is particularly well suited to thoracic surgery. Numerous studies in adults and children show cryoablation is effective at controlling postoperative pain and decreasing opioid use and LOS for both thoracoscopic and open operations. Although more long-term studies are needed, early evidence suggests there is reliable return of sensation to the chest wall and long-term neuropathic pain is rare.

Acknowledgments

Research was conducted by the authors of the article.

Authors' Contributions

K.L.: investigation and writing—original draft preparation, R.S.E.: investigation and writing—review and Editing, M.Z.: investigation and writing—original draft preparation, A.H.-V.: investigation, A.O.: investigation, and B.E.P.: supervision and writing—reviewing and editing.

Disclosure Statement

B.E.P. is an educational consultant for Atricure. K.L., R.S.E., M.Z., A.H.-V., and A.O. have no disclosure.

Funding Information

No funding was received for this article.

References

1. Caracalos A, Levita E, Cooper IS. A study of roentgeno-anatomic lesion location and results in cryosurgery of the basal ganglia. St Barnabas Hosp Med Bull 1962;1:24–32.
2. Lloyd JW, Barnard JD, Glynn CJ. Cryoanalgesia. A new approach to pain relief. Lancet 1976;2(7992):932–934.
3. Menorca RM, Fussell TS, Elfar JC. Nerve physiology: Mechanisms of injury and recovery. Hand Clin 2013;29(3): 317–330; doi: 10.1016/j.hcl.2013.04.002
4. Gordon T. Peripheral nerve regeneration and muscle reinnervation. Int J Mol Sci 2020;21(22):8652; doi: 10.3390/ijms21228652
5. Barnard D. The effects of extreme cold on sensory nerves. Ann R Coll Surg Engl 1980;62(3):180–187.
6. Zhou L, Kambin 0050, Casey KF, et al. Mechanism research of cryoanalgesia. Neurol Res 1995;17:307–311.
7. Seddon HJ. Three types of nerve injury. Brain 1943;66:237.
8. Sunderland S. A classification of peripheral nerve injuries producing loss of function. Brain 1951;74:491–516.
9. Hsu M, Stevenson FF. Reduction in muscular motility by selective focused cold therapy: A preclinical study. J Neural Transm (Vienna) 2014;121(1):15–20; doi: 10.1007/s00702-013-1077-y
10. Evans PJ, Lloyd JW, Green CJ. Cryoanalgesia: The response to alterations in freeze cycle and temperature. Br J Anaesth 1981;53(11):1121–1127; doi: 10.1093/bja/53.11.1121
11. Moorjani N, Zhao F, Tian Y, et al. Effects of cryoanalgesia on post-thoracotomy pain and on the structure of intercostal nerves: A human prospective randomized trial and a histological study. Eur J Cardiothorac Surg 2001;20(3):502–507.
12. Beazley RM, Bagley DH, Ketcham AS. The effect of cryosurgery on peripheral nerves. J Surg Res 1974;16(3): 231–234.
13. Erinjeri JP, Clark TW. Cryoablation: Mechanism of action and devices. J Vasc Interv Radiol 2010;21(8 Suppl):S187–S191; doi: 10.1016/j.jvir.2009.12.403
14. Trescot AM. Cryoanalgesia in interventional pain management. Pain Phys 2003;6(3):345–360.
15. cryoICE Cryoablation Probes. Atricure. Available from: https://www.atricure.com/healthcare-professionals/therapies/concomitant-surgical-ablation/cryoice-cryoablation-probes [Accessed June 24, 2022].
16. Baust JG, Gage AA. The molecular basis of cryosurgery. BJU Int 2005;95(9):1187–1191; doi: 10.1111/j.1464-410X.2005.05502.x
17. De Troyer A, Kirkwood PA, Wilson TA. Respiratory action of the intercostal muscles. Physiol Rev 2005;85(2):717–756; doi: 10.1152/physrev.00007.2004
18. Roussos C, Macklem PT. The respiratory muscles. N Engl J Med 1982;307(13):786–797; doi: 10.1056/NEJM198209233071304
19. Possley D, Luczak SB, Angus A, et al. T1–T2 disk herniation presenting with horner syndrome: A case report with literary review. J Am Acad Orthop Surg Glob Res Rev 2018;2(11):e016; doi: 10.5435/JAAOSGlobal-D-18-00016
20. AtriCure Instructions for use. AtriCure cryoSPHERE probe. Available from: https://www.atricure.com/sites/default/files/devices-ifu/IFU-0036.A.pdf [Accessed June 24, 2022].
21. Park R, Coomber M, Gilron I, et al. Cryoanalgesia for postsurgical pain relief in adults: A systematic review and meta-analysis. Ann Med Surg (Lond) 2021;69:102689; doi: 10.1016/j.amsu.2021.102689

22. Cha PI, Min JG, Patil A, et al. Efficacy of intercostal cryoneurolysis as an analgesic adjunct for chest wall pain after surgery or trauma: Systematic review. Trauma Surg Acute Care Open 2021;6:e000690; doi: 10.1136/tsaco-2021-000690
23. Lau WC, Shannon FL, Bolling SF, et al. Intercostal cryo nerve block in minimally invasive cardiac surgery: The prospective randomized FROST trial. Pain Ther 2021; 10(2):1579–1592; doi: 10.1007/s40122-021-00318-0
24. Tung J, Patel R, Rajwani T, et al. Feasibility and efficacy of cryoneurolysis analgesia in robotic-assisted thoracoscopic surgery (CARTS): A pilot study. J Robot Surg 2022;16(3):597–600; doi: 10.1007/s11701-021-01279-4
25. Finneran Iv JJ, Gabriel RA, Swisher MW, et al. Ultrasound-guided percutaneous intercostal nerve cryoneurolysis for analgesia following traumatic rib fracture-a case series. Korean J Anesthesiol 2020;73(5):455–459; doi: 10.4097/kja.19395
26. Bauman ZM, Loftus J, Raposo-Hadley A, et al. Surgical stabilization of rib fractures combined with intercostal nerve cryoablation proves to be more cost effective by reducing hospital length of stay and narcotics. Injury 2021; 52(5):1128–1132; doi: 10.1016/j.injury.2021.02.009
27. Choi J, Min JG, Jopling JK, et al. Intercostal nerve cryoablation during surgical stabilization of rib fractures. J Trauma Acute Care Surg 2021;91(6):976–980; doi: 10.1097/TA.0000000000003391
28. Zhao F, Vossler J, Kaye A. A multi-institution case series of intercostal nerve cryoablation for pain control when used in conjunction with surgical stabilization of rib fractures. J Cardiothorac Trauma 2019;4:28; doi: 10.4103/jctt.jctt_12_19
29. Densmore JC, Peterson DB, Stahovic LL, et al. Initial surgical and pain management outcomes after Nuss procedure. J Pediatr Surg 2010;45(9):1767–1771.
30. Hall Burton DM, Boretsky KR. A comparison of paravertebral nerve block catheters and thoracic epidural catheters for postoperative analgesia following the Nuss procedure for pectus excavatum repair. Paediatr Anaesth 2014;24(5):516–520.
31. Lukosiene L, Macas A, Trepenaitis D, et al. Single shot intercostal block for pain management in pediatric patients undergoing the Nuss procedure: A double-blind, randomized, controlled study. J Pediatr Surg 2014;49(12):1753–1757.
32. Choudhry DK, Brenn BR, Sacks K, et al. Continuous chest wall ropivacaine infusion for analgesia in children undergoing Nuss procedure: A comparison with thoracic epidural. Paediatr Anaesth 2016;26(6):582–589.
33. Loftus PD, Elder CT, Russell KW, et al. Paravertebral regional blocks decrease length of stay following surgery for pectus excavatum in children. J Pediatr Surg 2016; 51(1):149–153.
34. Bryskin RB, Robie DK, Mansfield FM, et al. Introduction of a novel ultrasound-guided extrathoracic sub-paraspinal block for control of perioperative pain in Nuss procedure patients. J Pediatr Surg 2017;52(3):484–491.
35. Singhal NR, Jones J, Semenova J, et al. Multimodal anesthesia with the addition of methadone is superior to epidural analgesia: A retrospective comparison of intraoperative anesthetic techniques and pain management for 124 pediatric patients undergoing the Nuss procedure. J Pediatr Surg 2016;51(4):612–616; doi: 10.1016/j.jpedsurg.2015.10.084
36. Keller BA, Kabagambe SK, Becker JC, et al. Intercostal nerve cryoablation versus thoracic epidural catheters for postoperative analgesia following pectus excavatum repair: Preliminary outcomes in twenty-six cryoablation patients. J Pediatr Surg 2016;51(12):2033–2038.
37. Graves CE, Moyer J, Zobel MJ, et al. Intraoperative intercostal nerve cryoablation During the Nuss procedure reduces length of stay and opioid requirement: A randomized clinical trial. J Pediatr Surg 2019;54(11):2250–2256; doi: 10.1016/j.jpedsurg.2019.02.057
38. Parrado R, Lee J, McMahon LE, et al. The use of cryoanalgesia in minimally invasive repair of pectus excavatum: Lessons learned. J Laparoendosc Adv Surg Tech A 2019; 29(10):1244–1251; doi: 10.1089/lap.2019.0203
39. Lai K, Notrica DM, McMahon LE, et al. Cryoablation in 350 Nuss procedures: Evolution of hospital length of stay and opioid use. J Pediatr Surg 2022:S0022-3468(22)00717-5; doi: 10.1016/j.jpedsurg.2022.10.051.
40. DiFiore JW, Robertson JO, Chhabada S, et al. Next day discharge after the Nuss procedure using intercostal nerve cryoablation, intercostal nerve blocks, and a perioperative ERAS pain protocol. J Pediatr Surg 2022;57(2):213–218; doi: 10.1016/j.jpedsurg.2021.10.034.
41. Rettig RL, Rudikoff AG, Annie Lo HY, et al. Same-day discharge following the Nuss repair: A comparison. J Pediatr Surg 2022;57(1):135–140; doi: 10.1016/j.jpedsurg.2021.09.023. Epub 2021 Sep 20. PMID: 34670678.
42. Zeineddin S, Goldstein SD, Linton S, et al. Effectiveness of one minute per level intercostal nerve cryoablation for postoperative analgesia after surgical correction of pectus excavatum. J Pediatr Surg 2023;58(1):34–40; doi: 10.1016/j.jpedsurg.2022.09.032.
43. Clark RA, Jacobson JC, Singhal A, et al. Impact of cryoablation on pectus excavatum repair in pediatric patients. J Am Coll Surg 2022;234(4):484–492; doi: 10.1097/XCS.0000000000000103
44. Rettig RL, Rudikoff AG, Lo HYA, et al. Cryoablation is associated with shorter length of stay and reduced opioid use in pectus excavatum repair. Pediatr Surg Int 2021; 37(1):67–75; doi: 10.1007/s00383-020-04778-x
45. Mehl SC, Sun RC, Anbarasu CR, et al. Association of intercostal nerve cryoablation during nuss procedure with complications and costs. Ann Thorac Surg 2022;S0003-4975(22)00572-0; doi: 10.1016/j.athoracsur.2022.04.022
46. Pilkington M, Harbaugh CM, Hirschl RB, et al. Use of cryoanalgesia for pain management for the modified ravitch procedure in children. J Pediatr Surg 2020;55(7):1381–1384; doi: 10.1016/j.jpedsurg.2019.09.016
47. Gologorsky R, Ewbank C, Idowu O, et al. Use of cryoanalgesia as a postoperative pain management for open pectus carinatum repair. Pediatr Surg Int 2021;37(1):179–181; doi: 10.1007/s00383-020-04768-z
48. Chen SY, Mack SJ, Stein JE, et al. Intercostal nerve cryoablation is associated with reduced opioid use in pediatric oncology patients. J Surg Res 2023;283:377–384; doi: 10.1016/j.jss.2022.11.004
49. Lai K, Eldredge RS, Nguyen M, et al. Initial outcomes using cryoablation in surgical management of slipping rib syndrome. J Pediatr Surg 2023; doi.org/10.1016/j.jpedsurg.2022.12.031
50. Graves C, Idowu O, Lee S, et al. Intraoperative cryoanalgesia for managing pain after the Nuss procedure. J Pediatr Surg 2017;52(6):920–924; doi: 10.1016/j.jpedsurg.2017.03.006

51. Yang MK, Cho CH, Kim YC. The effects of cryoanalgesia combined with thoracic epidural analgesia in patients undergoing thoracotomy. Anaesthesia 2004;59(11):1073–1077; doi: 10.1111/j.1365-2044.2004.03896.x
52. Mustola ST, Lempinen J, Saimanen E, et al. Efficacy of thoracic epidural analgesia with or without intercostal nerve cryoanalgesia for postthoracotomy pain. Ann Thorac Surg 2011;91(3):869–873; doi: 10.1016/j.athoracsur.2010.11.014
53. Gwak MS, Yang M, Hahm TS, et al. Effect of cryoanalgesia combined with intravenous continuous analgesia in thoracotomy patients. J Korean Med Sci 2004;19(1):74–78; doi: 10.3346/jkms.2004.19.1.74
54. Zobel MJ, Ewbank C, Mora R, et al. The incidence of neuropathic pain after intercostal cryoablation during the Nuss procedure. Pediatr Surg Int 2020;36(3):317–324; doi: 10.1007/s00383-019-04602-1
55. Pestronk A, Drachman DB, Griffin JW. Effects of aging on nerve sprouting and regeneration. Exp Neurol 1980;70(1):65–82.
56. Barrios C, de Pablos J. Surgical management of nerve injuries of the upper extremity in children: A 15-year survey. J Pediatr Orthop 1991;11(5):641–645.
57. Kovacic U, Sketelj J, Bajrovic FF. Chapter 26: Age-related differences in the reinnervation after peripheral nerve injury. Int Rev Neurobiol 2009;87:465–482.
58. Sun RC, Mehl SC, Anbarasu CR, et al. Intercostal cryoablation during Nuss procedure: A large volume single surgeon's experience and outcomes. J Pediatr Surg 2021;56(12):2229–2234; doi: 10.1016/j.jpedsurg.2021.03.006
59. Harbaugh CM, Johnson KN, Kein CE, et al. Comparing outcomes with thoracic epidural and intercostal nerve cryoablation after Nuss procedure. J Surg Res 2018;231:217–223; doi: 10.1016/j.jss.2018.05.048
60. Morikawa N, Laferriere N, Koo S, et al. Cryoanalgesia in patients undergoing nuss repair of pectus excavatum: Technique modification and early results. J Laparoendosc Adv Surg Tech A 2018;28(9):1148–1151; doi: 10.1089/lap.2017.0665
61. Kurz A, Sessler DI, Lenhardt R. Perioperative normothermia to reduce the incidence of surgical-wound infection and shorten hospitalization. Study of Wound Infection and Temperature Group. N Engl J Med 1996;334(19):1209–1215; doi: 10.1056/NEJM199605093341901
62. Arshad SA, Hatton GE, Ferguson DM, et al. Cryoanalgesia enhances recovery from minimally invasive repair of pectus excavatum resulting in reduced length of stay: A case-matched analysis of NSQIP-Pediatric patients. J Pediatr Surg 2021;56(7):1099–1102.
63. Lu Q, Han Y, Cao W, et al. Comparison of non-divided intercostal muscle flap and intercostal nerve cryoanalgesia treatments for post-oesophagectomy neuropathic pain control. Eur J Cardiothorac Surg 2013;43(3):e64–e70; doi: 10.1093/ejcts/ezs645
64. Bundrant NT, Sayrs LW, Ostlie D, et al. Infectious complications of intercostal nerve cryoablation mediated by perioperative hypothermia during pediatric Nuss procedure. J Pediatr Surg 2022;57(6):1083–1086; doi: 10.1016/j.jpedsurg.2022.01.044
65. Griauzde J, Gemmete JJ, Farley F. Successful treatment of a Musculoskeletal Tumor Society grade 3 aneurysmal bone cyst with N-butyl cyanoacrylate embolization and percutaneous cryoablation. J Vasc Interv Radiol 2015;26(6):905–909; doi: 10.1016/j.jvir.2015.01.019
66. Tedde ML, Campos JR, Das-Neves-Pereira JC, et al. The search for stability: Bar displacement in three series of pectus excavatum patients treated with the Nuss technique. Clinics (Sao Paulo) 2011;66(10):1743–1746; doi: 10.1590/s1807-59322011001000012
67. Pilegaard HK, Licht PB. Early results following the Nuss operation for pectus excavatum—A single-institution experience of 383 patients. Interact Cardiovasc Thorac Surg 2008;7(1):54–57; doi: 10.1510/icvts.2007.160937
68. Park HJ, Lee SY, Lee CS, et al. The Nuss procedure for pectus excavatum: Evolution of techniques and early results on 322 patients. Ann Thorac Surg 2004;77(1):289–295; doi: 10.1016/s0003-4975(03)01330-4
69. Lai K, Lee J, Notrica DM, et al. Intercostal nerve cryoablation in minimally invasive repair of pectus excavatum: Effect on pulmonary function. J Laparoendosc Adv Surg Tech A 2022;32(12):1244–1248; doi: 10.1089/lap.2022.0242
70. Rooney SM, Jain S, McCormack P, et al. A comparison of pulmonary function tests for postthoracotomy pain using cryoanalgesia and transcutaneous nerve stimulation. Ann Thorac Surg 1986;41(2):204–207; doi: 10.1016/s0003-4975(10)62670-7
71. Aiken TJ, Stahl CC, Lemaster D, et al. Intercostal nerve cryoablation is associated with lower hospital cost during minimally invasive Nuss procedure for pectus excavatum. J Pediatr Surg 2021;56(10):1841–1845; doi: 10.1016/j.jpedsurg.2020.10.009
72. Sujka J, Benedict L, Fraser JD, et al. Outcomes using cyroablation for postoperative pain control in children following minimally invasive pectus excavatum repair. J Laparoendosc Adv Surg Tech A 2018;28(11):1383–1386; doi: 10.1089/lap.2018.0111
73. Torre M, Mameli L, Bonfiglio R, et al. A new device for thoracoscopic cryoanalgesia in pectus excavatum repair: Preliminary single center experience. Front Pediatr 2021;8:614097.

Address correspondence to:
R. Scott Eldredge, MD
Division of Pediatric Surgery
Phoenix Children's Hospital
1919 E Thomas Road
Phoenix, AZ 85016
USA

E-mail: reldredge@phoenixchildrens.com